

Treating Trauma

Case studies and early experience with the Zenith Alpha Thoracic Endovascular Graft for treatment of blunt aortic injuries.

BY BENJAMIN W. STARNES, MD, FACS



Dramatic improvements have been made in the care of patients harboring vascular disease over the past 2 decades. Much of this progress has been made on the back of new device design. In 2008, the American Association for the Surgery of Trauma

published results on emerging trends in the management of blunt aortic injury (BAI) and stated that, "There is a major and urgent need for improvement of the available endovascular devices."¹ Industry responded to this call for better device design with improvements that have finally arrived. In 2010, I was invited by Cook Medical to serve as Principal Investigator for TRANSFIX, the national multicenter clinical trial evaluating the Zenith TX2 low-profile endovascular graft (now called Zenith Alpha Thoracic) for the management of patients presenting with BAI. The following is a description of a few cases using this device to manage severely injured patients with aortic injury.

DISCUSSION

The Zenith Alpha Thoracic device offers what amounts to a great breakthrough in managing patients with BAI. The low-profile, hydrophilic, braided sheath delivery system; precurved inner cannula (Figure 1); and nitinol-based stent design provide for unparalleled opportunity to treat a wide variety of patients. With the lowest treatable aortic diameter (15 mm), lowest arch radius indication (20 mm), and smallest-diameter

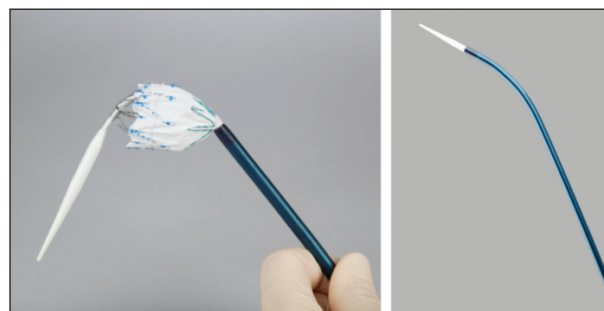


Figure 1. The precurved inner cannula.

delivery system (16 F), more patients can be treated with this newer-generation device. A comparison of Zenith Alpha Thoracic with its predecessor, Zenith TX2, is depicted in Table 1.

TRANSFIX TRIAL DESIGN AND SHORT-TERM RESULTS

Fifty patients were enrolled into the prospective, nonrandomized TRANSFIX trial between January 2013 and May 2014. Patients in the trial will be followed through 5 years. The primary safety endpoint is 30-day mortality, and the primary efficacy endpoint is 30-day device success. As presented at the 2014 annual meeting of the Society for Vascular Surgery, technical success was achieved in all patients (100%), and there were no intraoperative mortalities. Short-term results indicate that the Zenith Alpha Thoracic device appears safe and

TABLE 1. COMPARISON OF ZENITH ALPHA THORACIC VERSUS ZENITH TX2 CHARACTERISTICS

Characteristics	Zenith TX2	Zenith TX2-LP (Zenith Alpha Thoracic)
Introducer sheath size	20–24 F	16–20 F
Device diameter size	22–42 mm	18–46 mm
Aortic arch radius	> 35 mm	≥ 20 mm
Stent strut metal, shape	Stainless steel, Z	Nitinol, Z
Graft material	Standard Dacron	Thinner, more tightly woven Dacron
Fixation	Covered, proximal	Bare, rounded proximal

CASE STUDY

Figures 2 through 7 are a compilation of CT images obtained from six patients who were enrolled into this trial at the author's institution between June 2013 and May 2014. All of these patients experienced blunt force trauma to the thoracic aorta by way of differing mechanisms. The images are arranged such that the preoperative axial slice (panel A) and three-dimensional reconstruction (panel B) are paired and compared with the postoperative axial slice (panel C) and relevant three-dimensional reconstruction (panel D). In Figure 3, panel E represents an alternate obliquity demonstrating good apposition of the stent graft against the aortic arch.

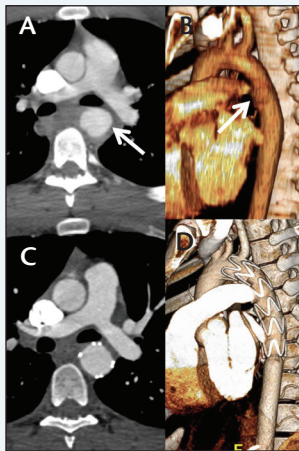


Figure 2.

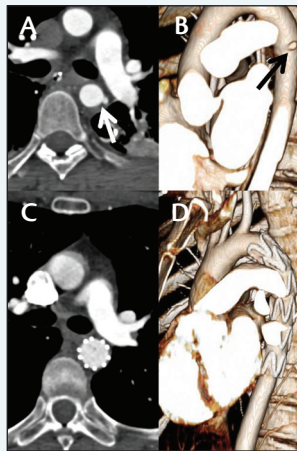


Figure 3.

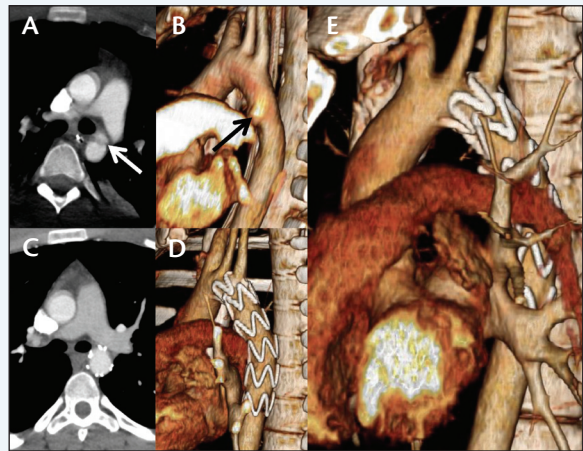


Figure 4.

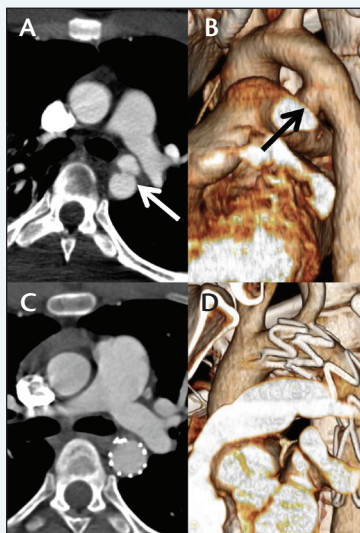


Figure 5.

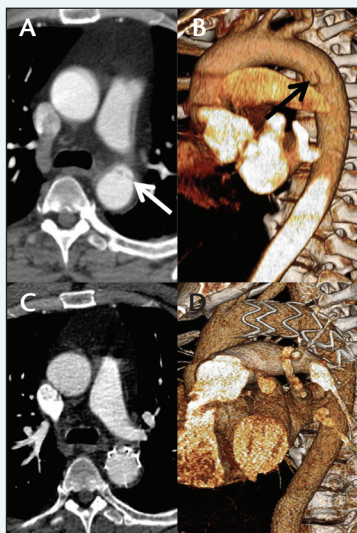


Figure 6.

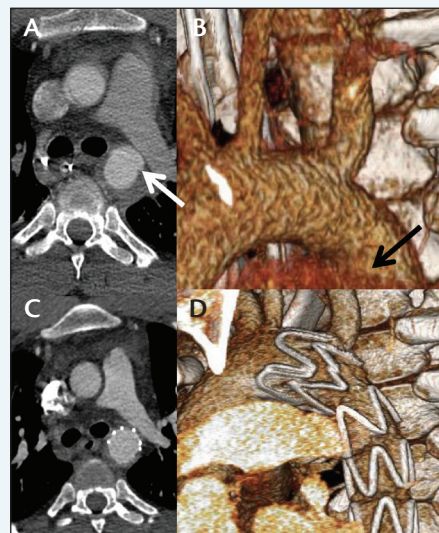


Figure 7.

effective for the management of patients with BAI. The results are currently under review by the US Food and Drug Administration and are the topic of a manuscript under preparation.

Other than access-related complications, the most feared complication of thoracic endovascular aortic repair for BAI is either stroke or paraplegia. Modern workup includes magnetic resonance (MR) imaging of the brain or spinal cord, respectively. In the past, the presence of ferrous stent graft designs in the thoracic aorta was a contraindication to MR imaging in these scenarios. The Zenith Alpha Thoracic device has improved compatibility with MR imaging, which allows for alternative imaging in challenging clinical scenarios.

CONCLUSION

Zenith Alpha Thoracic represents a powerful tool in our armamentarium for managing aortic pathology. The management of BAI has become a percutaneous, semielective procedure that can be performed in under

an hour. Thanks to better device design that includes a smaller, precurved delivery system and a nitinol frame, more patients with BAIs are candidates for this minimally invasive technology. ■

Benjamin W. Starnes, MD, FACS, is Professor and Chief, Division of Vascular Surgery; and Vice Chair, Department of Surgery, University of Washington in Seattle, Washington. He has disclosed that he is a Cofounder of Aortica. Dr. Starnes may be reached at starnes@uw.edu.

Disclaimer: The Zenith Alpha Thoracic Endovascular Graft is an investigational device in the United States and is limited by United States law to investigational use. It is CE Mark approved only for the indication of endovascular treatment of patients with aneurysms and ulcers in the descending thoracic aorta having vascular morphology suitable for endovascular repair.

1. Demetriades D, Velmahos GC, Scalea TM, et al. Operative repair or endovascular stent graft in blunt traumatic thoracic aortic injuries: results of an American Association for the Surgery of Trauma Multicenter Study. *J Trauma*. 2008;64:561-570; discussion 570-571.